



Protocol for the Examination of Specimens From Patients With Carcinoma of the Stomach

Version: 4.4.0.0

Protocol Posting Date: March 2023

CAP Laboratory Accreditation Program Protocol Required Use Date: December 2023

The changes included in this current protocol version affect accreditation requirements. The new deadline for implementing this protocol version is reflected in the above accreditation date.

For accreditation purposes, this protocol should be used for the following procedures AND tumor types:

Procedure	Description
Resection	Includes partial or complete gastrectomy
Tumor Type	Description
Carcinomas	Includes carcinomas involving the esophagogastric junction (EGJ) with tumor midpoint >2 cm into the proximal stomach and carcinomas of the cardia/proximal stomach without involvement of the EGJ even if tumor midpoint is ≤2 cm into the proximal stomach

This protocol is NOT required for accreditation purposes for the following:

Procedure
Excisional biopsy (includes endoscopic resection and polypectomy)
Primary resection specimen with no residual cancer (eg, following neoadjuvant therapy)
Recurrent tumor
Cytologic specimens

The following tumor types should NOT be reported using this protocol:

Tumor Type
Carcinoma involving the EGJ with center ≤2 cm into the proximal stomach (consider the Esophagus protocol)
Well-differentiated neuroendocrine tumor (consider the Stomach NET protocol)
Lymphoma (consider the Hodgkin or non-Hodgkin Lymphoma protocols)
Gastrointestinal stromal tumor (GIST) (consider the GIST protocol)
Non-GIST sarcoma (consider the Soft Tissue protocol)

Authors

Lawrence J. Burgart, MD*; William V. Chopp, MD*; Dhanpat Jain, MD*.

With guidance from the CAP Cancer and CAP Pathology Electronic Reporting Committees.

* Denotes primary author.

Accreditation Requirements

This protocol can be utilized for a variety of procedures and tumor types for clinical care purposes. For accreditation purposes, only the definitive primary cancer resection specimen is required to have the core and conditional data elements reported in a synoptic format.

- Core data elements are required in reports to adequately describe appropriate malignancies. For accreditation purposes, essential data elements must be reported in all instances, even if the response is “not applicable” or “cannot be determined.”
- Conditional data elements are only required to be reported if applicable as delineated in the protocol. For instance, the total number of lymph nodes examined must be reported, but only if nodes are present in the specimen.
- Optional data elements are identified with “+” and although not required for CAP accreditation purposes, may be considered for reporting as determined by local practice standards.

The use of this protocol is not required for recurrent tumors or for metastatic tumors that are resected at a different time than the primary tumor. Use of this protocol is also not required for pathology reviews performed at a second institution (ie, secondary consultation, second opinion, or review of outside case at second institution).

Synoptic Reporting

All core and conditionally required data elements outlined on the surgical case summary from this cancer protocol must be displayed in synoptic report format. Synoptic format is defined as:

- Data element: followed by its answer (response), outline format without the paired Data element: Response format is NOT considered synoptic.
- The data element should be represented in the report as it is listed in the case summary. The response for any data element may be modified from those listed in the case summary, including “Cannot be determined” if appropriate.
- Each diagnostic parameter pair (Data element: Response) is listed on a separate line or in a tabular format to achieve visual separation. The following exceptions are allowed to be listed on one line:
 - Anatomic site or specimen, laterality, and procedure
 - Pathologic Stage Classification (pTNM) elements
 - Negative margins, as long as all negative margins are specifically enumerated where applicable
- The synoptic portion of the report can appear in the diagnosis section of the pathology report, at the end of the report or in a separate section, but all Data element: Responses must be listed together in one location

Organizations and pathologists may choose to list the required elements in any order, use additional methods in order to enhance or achieve visual separation, or add optional items within the synoptic report. The report may have required elements in a summary format elsewhere in the report IN ADDITION TO but not as replacement for the synoptic report ie, all required elements must be in the synoptic portion of the report in the format defined above.

Summary of Changes

v 4.4.0.0

- Changed reporting requirements for WHO and Lauren Classifications of Adenocarcinoma

Reporting Template**Protocol Posting Date: March 2023****Select a single response unless otherwise indicated.****CASE SUMMARY: (STOMACH)****Standard(s):** AJCC-UICC 8**SPECIMEN (Note A)****Procedure**

- Endoscopic resection
- Partial gastrectomy, proximal
- Partial gastrectomy, distal
- Partial gastrectomy, other (specify): _____
- Total gastrectomy
- Other (specify): _____
- Not specified

TUMOR**Tumor Site (Note B) (select all that apply)***Use the esophageal checklist if the tumor involves the EGJ and the tumor midpoint is 2 cm or less into the proximal stomach.*

- Cardia: _____
- Fundus: _____
- Anterior wall
- Posterior wall
- Body: _____
- Anterior wall
- Posterior wall
- Lesser curvature
- Greater curvature
- Antrum: _____
- Anterior wall
- Posterior wall
- Lesser curvature
- Greater curvature
- Pylorus: _____
- Other (specify): _____
- Not specified

Histologic Type (Note C) Adenocarcinoma**Adenocarcinoma Classification (based on WHO)**

- Tubular adenocarcinoma
- Poorly cohesive carcinoma (includes signet-ring cell carcinoma and other variants)
- Mucinous adenocarcinoma (greater than 50% mucinous)
- Papillary adenocarcinoma

___ Mixed carcinoma (mixture of discrete glandular (tubular / papillary) and signet-ring / poorly cohesive cellular histological components): _____

+Lauren Classification of Adenocarcinoma

___ Intestinal type

___ Diffuse type (includes signet-ring carcinoma, classified as greater than 50% signet-ring cells)

___ Mixed (approximately equal amounts of intestinal and diffuse)

___ Other (specify): _____

___ Cannot be determined

___ Hepatoid adenocarcinoma

___ (Adeno)carcinoma with lymphoid stroma

___ Micropapillary adenocarcinoma

___ Adenocarcinoma of fundic-gland type

___ Squamous cell carcinoma

___ Adenosquamous carcinoma

___ Undifferentiated (anaplastic) carcinoma

___ Gastroblastoma

___ Large cell neuroendocrine carcinoma

___ Small cell neuroendocrine carcinoma

Select this option only if large cell or small cell cannot be determined.

___ Neuroendocrine carcinoma (poorly differentiated)#

___ Mixed adenocarcinoma-neuroendocrine carcinoma (small cell or large cell neuroendocrine carcinoma)

___ Mixed adenocarcinoma-neuroendocrine tumor

___ Other histologic type not listed (specify): _____

+Histologic Type Comment: _____

Histologic Grade (Note [D](#))

___ G1, well differentiated

___ G2, moderately differentiated

___ G3, poorly differentiated, undifferentiated

___ Other (specify): _____

___ GX, cannot be assessed: _____

___ Not applicable: _____

Tumor Size

___ Greatest dimension in Centimeters (cm): _____ cm

+Additional Dimension in Centimeters (cm): ___ x ___ cm

___ Cannot be determined (explain): _____

Tumor Extent

___ Carcinoma in situ (intraepithelial tumor without invasion of the lamina propria, high-grade dysplasia)

___ Invades lamina propria

___ Invades muscularis mucosae

___ Invades submucosa

___ Invades muscularis propria

___ Penetrates subserosal connective tissue without invasion of visceral peritoneum or adjacent structures

___ Invades serosa (visceral peritoneum)

Intramural extension to the duodenum or esophagus is not considered invasion of an adjacent structure, but is classified using the depth of the greatest invasion in any of these sites.

___ Directly invades adjacent structure(s) or organ(s)#

___ Spleen

___ Transverse colon

___ Liver

___ Diaphragm

___ Pancreas

___ Abdominal wall

___ Adrenal gland

___ Kidney

___ Small Intestine

___ Retroperitoneum

___ Other (specify): _____

___ Cannot be determined: _____

___ Cannot be determined: _____

___ No evidence of primary tumor

Treatment Effect (Note E)

___ No known presurgical therapy

___ Present, with no viable cancer cells (complete response, score 0)

___ Present, with single cells or rare small groups of cancer cells (near complete response, score 1)

___ Present, with residual cancer showing evident tumor regression, but more than single cells or rare small groups of cancer cells (partial response, score 2)

___ Present (not otherwise specified)

___ Absent, with extensive residual cancer and no evident tumor regression (poor or no response, score 3)

___ Cannot be determined

Lymphatic and / or Vascular Invasion (Note F)

___ Not identified

___ Present

___ Cannot be determined: _____

+Perineural Invasion (Note G)

___ Not identified

___ Present

___ Cannot be determined: _____

+Tumor Comment: _____

MARGINS (Note H)

Margin Status for Invasive Carcinoma

___ All margins negative for invasive carcinoma

+Closest Margin(s) to Invasive Carcinoma (select all that apply)

- Proximal: _____
- Distal: _____
- Omental (radial): _____
- Mucosal: _____
- Deep: _____
- Other (specify): _____
- Cannot be determined: _____

+Distance from Invasive Carcinoma to Closest Margin

Specify in Centimeters (cm)

- Exact distance in cm: _____ cm
- Greater than 1 cm

Specify in Millimeters (mm)

- Exact distance in mm: _____ mm
- Greater than 10 mm

Other

- Other (specify): _____
- Cannot be determined: _____

Invasive carcinoma present at margin

Margin(s) Involved by Invasive Carcinoma (select all that apply)

- Proximal: _____
- Distal: _____
- Greater omental: _____
- Lesser omental: _____
- Omental (radial): _____
- Mucosal: _____
- Deep: _____
- Other (specify): _____
- Cannot be determined: _____
- Other (specify): _____
- Cannot be determined (explain): _____
- Not applicable

Margin Status for Dysplasia (select all that apply)

- All margins negative for dysplasia
- Carcinoma in situ (high-grade dysplasia) present at margin

Margin(s) Involved by Carcinoma in Situ (select all that apply)

- Proximal: _____
- Distal: _____
- Mucosal: _____
- Other (specify): _____
- Cannot be determined: _____
- Low-grade dysplasia present at margin

Margin(s) Involved by Low-Grade Dysplasia (select all that apply)

- Proximal: _____
- Distal: _____
- Mucosal: _____

- Other (specify): _____
- Cannot be determined: _____
- Other (specify): _____
- Cannot be determined (explain): _____
- Not applicable

+Margin Comment: _____

REGIONAL LYMPH NODES (Note I)

Regional Lymph Node Status

- Not applicable (no regional lymph nodes submitted or found)
- Regional lymph nodes present
 - All regional lymph nodes negative for tumor
 - Tumor present in regional lymph node(s)

Number of Lymph Nodes with Tumor

- Exact number (specify): _____
- At least (specify): _____
- Other (specify): _____
- Cannot be determined (explain): _____
- Other (specify): _____
- Cannot be determined (explain): _____

Number of Lymph Nodes Examined

- Exact number (specify): _____
- At least (specify): _____
- Other (specify): _____
- Cannot be determined (explain): _____

+Regional Lymph Node Comment: _____

DISTANT METASTASIS

Distant Site(s) Involved, if applicable (select all that apply)

- Not applicable
- Non-regional lymph node(s): _____
- Liver: _____
- Other (specify): _____
- Cannot be determined: _____

pTNM CLASSIFICATION (AJCC 8th Edition) (Note J)

Reporting of pT, pN, and (when applicable) pM categories is based on information available to the pathologist at the time the report is issued. As per the AJCC (Chapter 1, 8th Ed.) it is the managing physician's responsibility to establish the final pathologic stage based upon all pertinent information, including but potentially not limited to this pathology report.

Modified Classification (required only if applicable) (select all that apply)

- Not applicable
- y (post-neoadjuvant therapy)
- r (recurrence)

pT Category

pT not assigned (cannot be determined based on available pathological information)

pT0: No evidence of primary tumor

pTis: Carcinoma in situ: intraepithelial tumor without invasion of the lamina propria, high-grade dysplasia

pT1: Tumor invades the lamina propria, muscularis mucosae, or submucosa

pT1a: Tumor invades the lamina propria or muscularis mucosae

pT1b: Tumor invades the submucosa

pT1 (subcategory cannot be determined)

A tumor may penetrate the muscularis propria with extension into the gastrocolic or gastrohepatic ligaments, or into the greater or lesser omentum, without perforation of the visceral peritoneum covering these structures. In this case, the tumor is classified as T3. If there is perforation of the visceral peritoneum covering the gastric ligaments or the omentum, the tumor should be classified as T4.

pT2: Tumor invades the muscularis propria#

The adjacent structures of the stomach include the spleen, transverse colon, liver, diaphragm, pancreas, abdominal wall, adrenal gland, kidney, small intestine, and retroperitoneum.

Intramural extension to the duodenum or esophagus is not considered invasion of an adjacent structure, but is classified using the depth of the greatest invasion in any of these sites.

pT3: Tumor penetrates the subserosal connective tissue without invasion of the visceral peritoneum or adjacent structures###, ###

pT4: Tumor invades the serosa (visceral peritoneum) or adjacent structures##, ###

pT4a: Tumor invades the serosa (visceral peritoneum)

pT4b: Tumor invades adjacent structures / organs

pT4 (subcategory cannot be determined)

T Suffix (required only if applicable)

Not applicable

(m) multiple primary synchronous tumors in a single organ

pN Category#

Metastatic tumor deposits in the subserosal fat adjacent to a gastric carcinoma, without evidence of residual lymph node tissue, are considered regional lymph node metastases for purposes of gastric cancer staging.

pN not assigned (no nodes submitted or found)

pN not assigned (cannot be determined based on available pathological information)

pN0: No regional lymph node metastasis

pN1: Metastasis in one or two regional lymph nodes

pN2: Metastasis in three to six regional lymph nodes

pN3: Metastasis in seven or more regional lymph nodes

pN3a: Metastasis in seven to 15 regional lymph nodes

pN3b: Metastasis in 16 or more regional lymph nodes

pN3 (subcategory cannot be determined)

pM Category (required only if confirmed pathologically)

Not applicable - pM cannot be determined from the submitted specimen(s)

pM1: Distant metastasis

ADDITIONAL FINDINGS (Note [K](#))**+Additional Findings (select all that apply)**

None identified

- Intestinal metaplasia
- Low-grade dysplasia
- High-grade dysplasia
- Chronic gastritis
- Helicobacter pylori present
- Polyp(s) (type[s]): _____
- Autoimmune atrophic chronic gastritis
- Other (specify): _____

SPECIAL STUDIES

For HER2 reporting, the CAP Gastric HER2 Template should be used. Pending biomarker studies should be listed in the Comments section of this report.

COMMENTS

Comment(s): _____

Explanatory Notes

A. Application

This protocol applies to all carcinomas that arise in the stomach, including:

- 1) Carcinomas involving the esophagogastric junction (EGJ) with tumor midpoint >2 cm into the proximal stomach
- 2) Carcinomas of the cardia/proximal stomach without involvement of the EGJ even if tumor midpoint is ≤ 2 cm into the proximal stomach

This protocol DOES NOT apply to:

- 1) Carcinomas involves the EGJ with tumor midpoint ≤ 2 cm into the proximal stomach (use CAP protocol for esophageal cancer)
- 2) Well-differentiated neuroendocrine tumors (use CAP protocol for neuroendocrine tumors of the stomach)
- 3) Lymphomas, gastrointestinal stromal tumors, and sarcomas.

B. Tumor Site

Tumor location should be described in relation to the following landmarks (Figure 1):

- gastric region: cardia, fundus, body, antrum, pylorus
- greater curvature, lesser curvature
- anterior wall, posterior wall

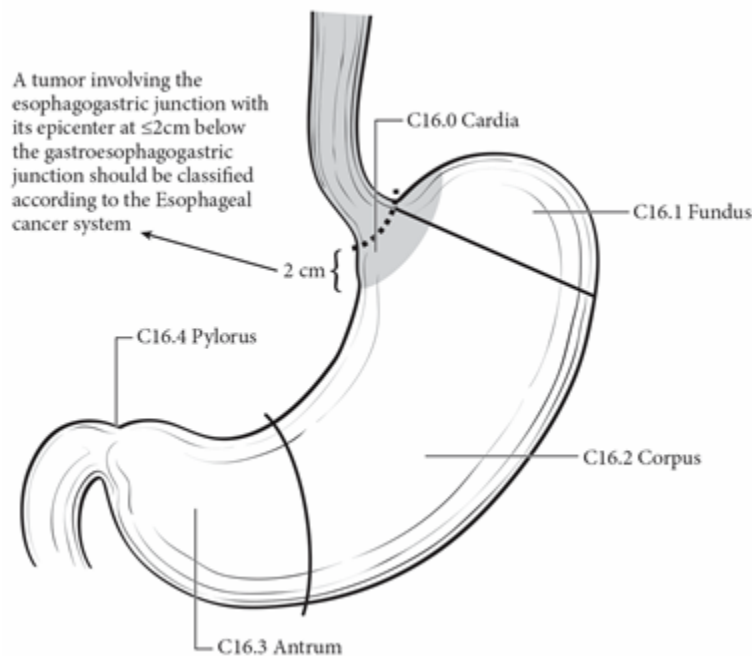


Figure 1. Anatomical subsites of the stomach. Used with permission of the American Joint Committee on Cancer (AJCC), Chicago, Illinois. The original and primary source for this information is the *AJCC Cancer Staging Manual*, Eighth Edition (2017) published by Springer Science+Business Media.

Tumors involving the EGJ with a midpoint \leq 2cm into the proximal stomach are classified for purposes of staging as esophageal carcinomas,¹ and the CAP protocol for the esophagus should be used for such tumors. Tumors involving the EGJ with a midpoint $>$ 2 cm into the proximal stomach and any tumors in the stomach, including cardia cancers, without involvement of the EGJ should use the CAP protocol for the stomach.

The proximal stomach located immediately below the diaphragm is cardia. The remaining portions are the fundus and the body. The distal portion of the stomach is the antrum. The pylorus is composed of muscular ring and a connection between the antrum and the first portion of the duodenum. The medial curvature of the stomach is the lesser curvature, whereas the lateral curvature is the greater curvature. The EGJ is defined as the junction of the tubular esophagus and the stomach irrespective of the type of epithelial lining of the esophagus.

References

1. Amin MB, Edge SB, Greene FL, et al, eds. *AJCC Cancer Staging Manual*. 8th ed. New York, NY: Springer; 2017.

C. Histologic Type

For consistency in reporting, the recently revised histologic classification proposed by the WHO is recommended¹ (Table 1) but not required for clinical use. However, this classification scheme does not distinguish between intestinal and diffuse types of gastric carcinoma but includes signet-ring cell carcinoma in the poorly cohesive carcinoma category. Thus, the Laurén classification² may be used in conjunction with the WHO system.

With the exception of the rare small cell carcinoma of the stomach, which has an unfavorable prognosis, most multivariate analyses show no effect of tumor type, independent of stage, on prognosis.³

Table 1. WHO Classification of Carcinoma of the Stomach²

Tumor Type	Histologic Features
Adenocarcinoma	
Papillary adenocarcinoma	Exophytic with elongated frond-like tumor extensions with fibrovascular cores; usually low grade.
Tubular adenocarcinoma	Dilated or slit-like branching tubules; usually low grade, although poorly differentiated variants are described.
Mucinous adenocarcinoma	Contains more than 50% extracellular mucin pools. May contain scattered signet-ring cells.
Poorly cohesive carcinomas, including signet-ring cell carcinoma and other variants	Tumor cells infiltrate as isolated single cells or small aggregates. Signet ring cell carcinoma is predominantly composed of signet-ring cells containing a clear droplet of cytoplasmic mucin displacing the nucleus. Other variants of poorly cohesive carcinoma may resemble mononuclear inflammatory cells.
Mixed carcinoma	Mixture of morphologically identifiable components such as tubular, papillary, and poorly cohesive patterns.
Adenocarcinoma, other histologic subtypes	
(Adeno)carcinoma with lymphoid stroma	Irregular sheets, trabeculae, ill-defined tubules or syncytia of polygonal cells embedded with a prominent lymphoid infiltrate in the stroma, with intraepithelial lymphocytes. Associated with Epstein-Barr virus infection and

Tumor Type	Histologic Features
Hepatoid adenocarcinoma	may have a more favorable prognosis. Less commonly associated with microsatellite instability and/or mismatch repair deficiency Large polygonal eosinophilic tumor cells resembling hepatocytes; may express alpha-fetoprotein.
Micropapillary adenocarcinoma	Micropapillary component in 10-90% of the tumor area
Adenocarcinoma of fundic-gland type	Include chief-cell predominant (most common), parietal cell-predominant, and mixed phenotype
Adenosquamous carcinoma	Mixture of glandular and squamous neoplastic components; the squamous component should comprise at least 25% of tumor volume
Squamous cell carcinoma	Keratinizing and nonkeratinizing forms are encountered.
Undifferentiated (anaplastic) carcinoma	diffuse sheets of anaplastic, large to medium size polygonal cells with frequent pleomorphic tumor giant cells; other morphologies include rhabdoid cell, sarcomatoid pleomorphic pattern, undifferentiated carcinoma with osteoclast-like giant cells, carcinoma with lymphoepithelioma-like feature, and glandular.
Gastroblastoma	Uniform spindle cells and uniform epithelial cells arranged in nests
Neuroendocrine carcinoma	Poorly differentiated high-grade carcinoma often with diffuse synaptophysin expression and faint or focal positivity for chromogranin A. These tumors exhibit a high mitotic rate (>20 per 10 high power fields, or Ki-67 index >20%), marked nuclear atypia, and may have focal necrosis
Large cell neuroendocrine carcinoma	Tumor cells are large, with moderate amount of cytoplasm, and may contain prominent nucleoli.
Small cell neuroendocrine carcinoma	Tumor cells are small, with finely granular chromatin and indistinct nucleoli.
Mixed neuroendocrine non-neuroendocrine neoplasm	
Mixed adenocarcinoma-neuroendocrine carcinoma	Composed of both gland-forming and neuroendocrine malignant elements, with at least 30% of each component. Identification of scattered neuroendocrine cells in adenocarcinomas by immunohistochemistry does not qualify as mixed carcinoma.
Mixed adenocarcinoma-neuroendocrine tumor	Composed of both adenocarcinoma and neuroendocrine tumor with each component $\geq 30\%$

For well-differentiated neuroendocrine tumors, the CAP protocol for neuroendocrine tumors of the stomach applies.

The Laurén classification, namely intestinal, diffuse, or mixed type, and/or the Ming classification, namely expanding or infiltrating type, may also be included. In general, significant correlation is seen between the various classification systems.⁴

The WHO classifies premalignant lesions of the gastrointestinal tract as intraepithelial neoplasia. For purposes of data reporting, high-grade dysplasia in a gastric resection specimen is reported as “carcinoma in situ.” The term “carcinoma in situ” is not widely applied to glandular neoplastic lesions in the gastrointestinal tract but is retained for tumor registry reporting purposes as specified by law in many states.

References

1. WHO Classification of Tumours Editorial Board. *Digestive system tumours*. Lyon (France): International Agency for Research on Cancer; 2019. (WHO classification of tumours series, 5th ed.; vol. 1).
2. Lauren P. The two histological main types of gastric carcinoma. *Acta Pathol Microbiol Scand*. 1965;64:31-49.
3. Talamonti MS, Kim SP, Yao KA, et al. Surgical outcomes of patients with gastric carcinoma: the importance of primary tumor location and microvessel invasion. *Surgery*. Oct 2003;134(4):720-727; discussion 727-729.
4. Luebke T, Baldus SE, Grass G, et al. Histological grading in gastric cancer by Ming classification: correlation with histopathological subtypes, metastasis, and prognosis. *World J Surg*. 2005;29(11):1422-1427; discussion 1428.

D. Histologic Grade

G	G Definition
GX	Grade cannot be assessed
G1	Well differentiated
G2	Moderately differentiated
G3	Poorly differentiated, undifferentiated

For adenocarcinomas, a histologic grading system that is based on the extent of glandular differentiation is suggested, as shown below.

Grade X	Cannot be assessed
Grade 1	Well differentiated (greater than 95% of tumor composed of glands)
Grade 2	Moderately differentiated (50% to 95% of tumor composed of glands)
Grade 3	Poorly differentiated (49% or less of tumor composed of glands)

Signet-ring cell carcinomas are high grade and are classified as grade 3.

In the AJCC 8th edition, undifferentiated carcinoma is grouped together with poorly differentiated carcinoma as grade 3. Small cell neuroendocrine carcinomas, which were classified as grade 4, are now considered as grade 3.

Although grade has been shown to have little impact on survival for patients undergoing complete tumor resection,¹ it has a significant impact on margin-negative resectability, with higher grade tumors less likely to be resectable.

References

1. Inoue K, Nakane Y, Michiura T, et al. Histopathological grading does not affect survival after R0 surgery for gastric cancer. *Eur J Surg Oncol*. 2002;28(6):633-636.

E. Treatment Effect

Response of tumor to previous chemotherapy or radiation therapy should be reported. Although grading systems for tumor response have not been established, in general, 3-category systems provide good interobserver reproducibility.¹ The following system is suggested:

Description	Tumor Regression Score
No viable cancer cells (complete response)	0
Single cells or rare small groups of cancer cells (near complete response)	1
Residual cancer with evident tumor regression, but more than single cells or rare small groups of cancer cells (partial response)	2
Extensive residual cancer with no evident tumor regression (poor or no response)	3

Sizable pools of acellular mucin may be present after chemoradiation but should not be interpreted as representing residual tumor.

This protocol does not preclude the use of other systems for assessment of tumor response, such as the schemes reported by Memorial Sloan-Kettering Cancer Center investigators and others.^{2,3}

References

1. Ryan R, Gibbons D, Hyland JMP, et al. Pathological response following long-course neoadjuvant chemoradiotherapy for locally advanced rectal cancer. *Histopathology*. 2005;47:141-146.
2. Mansour JC, Tang L, Shah M, et al. Does graded histologic response after neoadjuvant chemotherapy predict survival for completely resected gastric cancer? *Ann Surg Oncol*. 2007;14(12):3412-3418
3. Rohatgi PR, Mansfield PF, Crane CH, et al. Surgical pathology stage by American Joint Commission on Cancer criteria predicts patient survival after preoperative chemoradiation for localized gastric carcinoma. *Cancer*. 2006;107(7):1475-1482.

F. Lymphovascular invasion

Both venous¹ and lymphatic vessel² invasion have been shown to be adverse prognostic factors³ and are predictive of lymph node metastases in early gastric cancers.⁴ However, the microscopic presence of tumor in lymphatic vessels or veins does not qualify as local extension of tumor as defined by the T classification (also see Note I).⁵

References

1. Fotia G, Marrelli D, De Stefano A, Pinto E, Roviello F. Factors influencing outcome in gastric cancer involving muscularis and subserosal layer. *Eur J Surg Oncol*. 2004;30(9):930-934.
2. Talamonti MS, Kim SP, Yao KA, et al. Surgical outcomes of patients with gastric carcinoma: the importance of primary tumor location and microvessel invasion. *Surgery*. Oct 2003;134(4):720-727; discussion 727-729.
3. Mansour JC, Tang L, Shah M, et al. Does graded histologic response after neoadjuvant chemotherapy predict survival for completely resected gastric cancer? *Ann Surg Oncol*. 2007;14(12):3412-3418
4. An JY, Baik YH, Choi MG, Noh JH, Sohn TS, Kim S. Predictive factors for lymph node metastasis in early gastric cancer with submucosal invasion: analysis of a single institutional experience. *Ann Surg*. 2007;246(5):749-753.
5. Amin MB, Edge SB, Greene FL, et al, eds. *AJCC Cancer Staging Manual*. 8th ed. New York, NY: Springer; 2017

G. Perineural Invasion

Perineural invasion has been shown to be an adverse prognostic factor¹ and has been associated with lymph node metastases in early gastric cancer in univariate but not multivariate analyses.²

References

1. Mansour JC, Tang L, Shah M, et al. Does graded histologic response after neoadjuvant chemotherapy predict survival for completely resected gastric cancer? *Ann Surg Oncol.* 2007;14(12):3412-3418.
2. An JY, Baik YH, Choi MG, Noh JH, Sohn TS, Kim S. Predictive factors for lymph node metastasis in early gastric cancer with submucosal invasion: analysis of a single institutional experience. *Ann Surg.* 2007;246(5):749-753.

H. Margins

For surgical resection specimens, margins include the proximal, distal, and radial margins. The radial margins represent the nonperitonealized soft tissue margins closest to the deepest penetration of tumor. In the stomach, the lesser omental (hepatoduodenal and hepatogastric ligaments) and greater omental resection margins are the only radial margins. For endoscopic resection specimens, margins include peripheral mucosal margins and the deep margin of resection. It may be helpful to mark the margin(s) closest to the tumor with ink. Margins marked by ink should be designated in the macroscopic description.

I. Regional Lymph Nodes

The specific regional nodal areas of the stomach (Figure 2) are listed below.¹

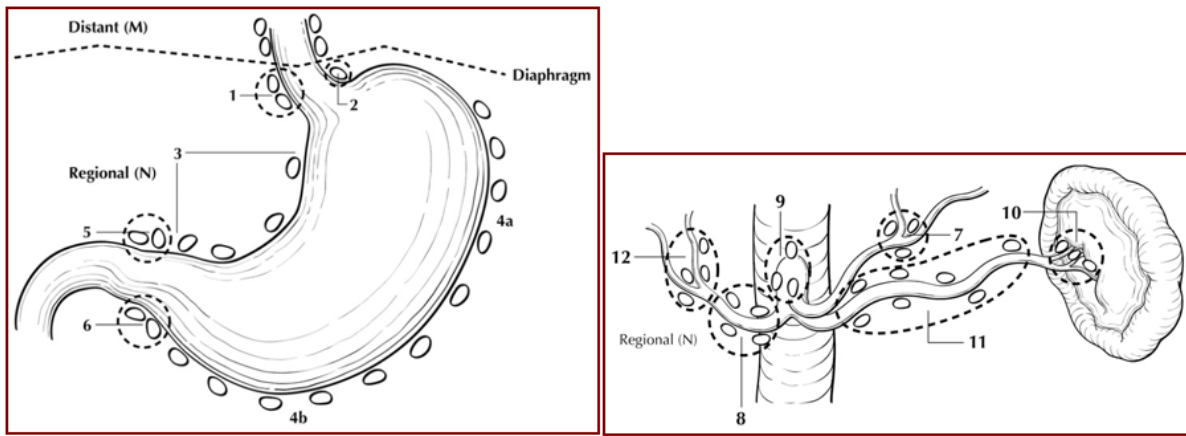


Figure 2. Regional lymph nodes of the stomach. Used with permission of the American Joint Committee on Cancer (AJCC), Chicago, IL. The original source for this material is the *AJCC Cancer Staging Atlas* (2006) edited by Greene et al² and published by Springer Science and Business Media, LLC, www.springerlink.com.

- Perigastric along the greater curvature (including greater curvature, greater omental)
- Perigastric along the lesser curvature (including lesser curvature, lesser omental)
- Right and left paracardial (cardioesophageal)
- Suprapyloric (including gastroduodenal)
- Infrapyloric (including gastroepiploic)

- Left gastric artery
- Celiac artery
- Common hepatic artery
- Hepatoduodenal (along the proper hepatic artery, including portal)
- Splenic artery
- Splenic hilum

For gastrectomy specimens, at least 16 regional lymph nodes should be removed and assessed pathologically.

Involvement of other intra-abdominal lymph nodes, such as retropancreatic, pancreaticoduodenal, peripancreatic, superior mesenteric, middle colic, para-aortic, or retroperitoneal nodes, is classified as distant metastasis.¹

References

1. Amin MB, Edge SB, Greene FL, et al, eds. *AJCC Cancer Staging Manual*. 8th ed. New York, NY: Springer; 2017.
2. Greene FL, Compton, CC, Fritz AG, et al, eds. *AJCC Cancer Staging Atlas*. New York: Springer; 2006.

J. Pathologic Stage Classification

The TNM staging system for gastric carcinoma of the American Joint Committee on Cancer (AJCC) and the International Union Against Cancer (UICC) is recommended and shown below.¹

According to AJCC/UICC convention, the designation “T” refers to a primary tumor that has not been previously treated. The symbol “p” refers to the pathologic classification of the TNM, as opposed to the clinical classification, and is based on gross and microscopic examination. pT entails a resection of the primary tumor or biopsy adequate to evaluate the highest pT category, pN entails removal of nodes adequate to validate lymph node metastasis, and pM implies microscopic examination of distant lesions. Clinical classification (cTNM) is usually carried out by the referring physician before treatment during initial evaluation of the patient or when pathologic classification is not possible.

Pathologic staging is usually performed after surgical resection of the primary tumor. Pathologic staging depends on pathologic documentation of the anatomic extent of disease, whether or not the primary tumor has been completely removed. If a biopsied tumor is not resected for any reason (eg, when technically infeasible) and if the highest T and N categories or the M1 category of the tumor can be confirmed microscopically, the criteria for pathologic classification and staging have been satisfied without total removal of the primary cancer.

TNM Descriptors

For identification of special cases of TNM or pTNM classifications, the “m” suffix and “y,” “r,” and “a” prefixes are used. In the AJCC 8th edition, “y” affects the stage grouping.

The “m” suffix indicates the presence of multiple primary tumors in a single site and is recorded in parentheses: pT(m)NM.

The “y” prefix indicates those cases in which classification is performed during or after initial multimodality therapy (ie, neoadjuvant chemotherapy, radiation therapy, or both chemotherapy and radiation therapy). The cTNM or pTNM category is identified by a “y” prefix. The ycTNM or ypTNM categorizes the extent of tumor actually present at the time of that examination. The “y” categorization is not an estimate of tumor before multimodality therapy (ie, before initiation of neoadjuvant therapy).

The “r” prefix indicates a recurrent tumor when staged after a documented disease-free interval and is identified by the “r” prefix: rTNM.

The “a” prefix designates the stage determined at autopsy: aTNM.

Lymphovascular Invasion

Lymphovascular invasion (LVI) indicates whether microscopic lymphatic and/or vascular invasion is identified in the pathology report. LVI includes lymphatic invasion, vascular invasion, or lymph-vascular invasion. By AJCC/UICC convention, LVI does not affect the T category indicating local extent of tumor unless specifically included in the definition of a T category (also see Note G).

T Category Considerations (Figures 3-5)

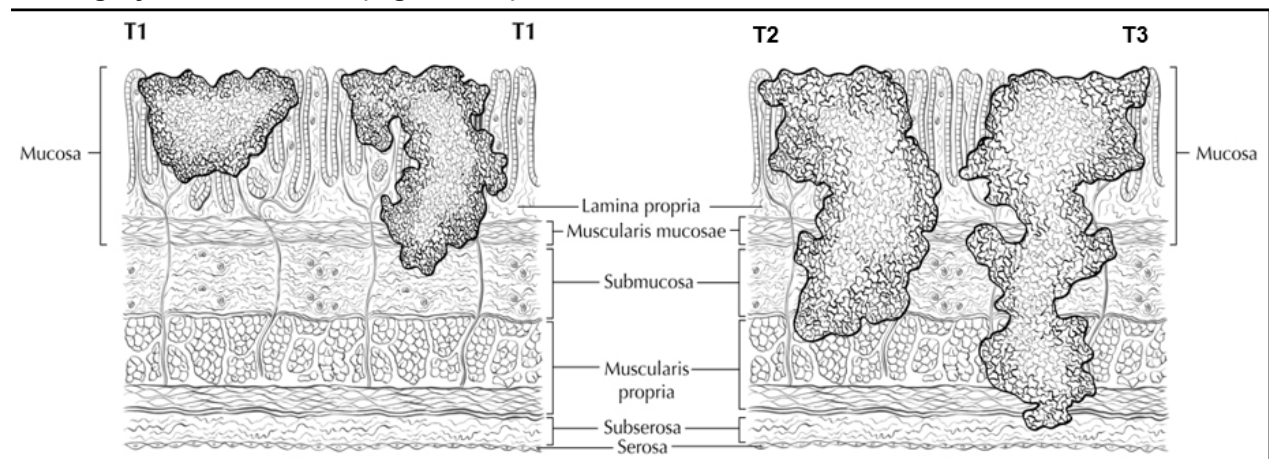


Figure 3. Definitions of T1, T2, and T3. Tumor invading the lamina propria is classified as T1a (left side in T1 illustration), whereas tumor invading the submucosa is classified as T1b (right side). T2 tumor invades the muscularis propria. T3 tumor invades the subserosal adipose tissue. Used with permission of the American Joint Committee on Cancer (AJCC), Chicago, IL. The original source for this material is the *AJCC Cancer Staging Atlas* (2006) edited by Greene et al² and published by Springer Science and Business Media, LLC, www.springerlink.com.

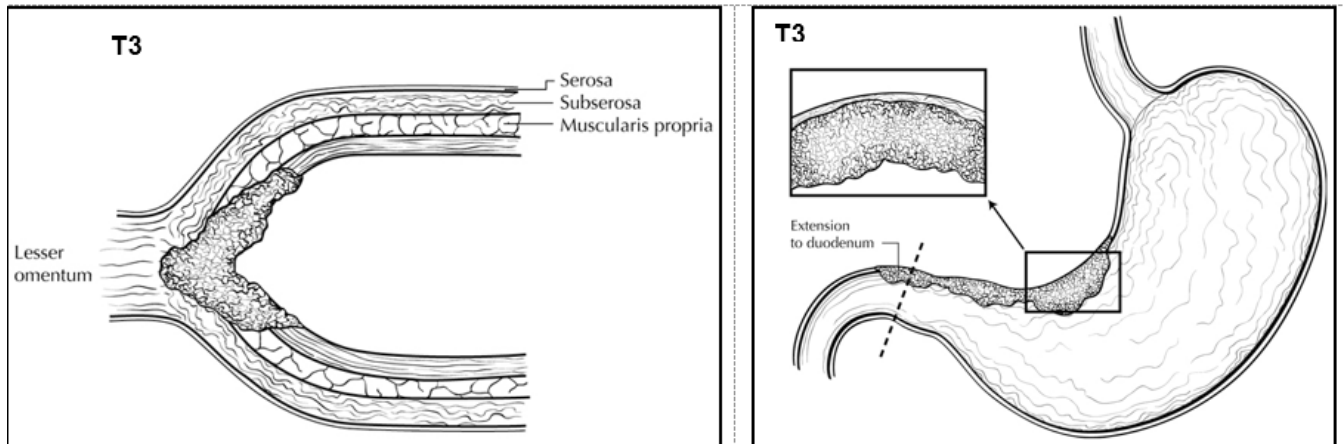


Figure 4. T3 is defined as tumor that invades the subserosa. A T3 tumor may penetrate the muscularis propria with extension into the gastrocolic or gastrohepatic ligaments, or into the greater or lesser omentum (upper panel), without perforation of the visceral peritoneum covering these structures. Distal extension to duodenum (lower panel) does not affect T category. Used with permission of the American Joint Committee on Cancer (AJCC), Chicago, IL. The original source for this material is the *AJCC Cancer Staging Atlas* (2006) edited by Greene et al² and published by Springer Science and Business Media, LLC, www.springerlink.com

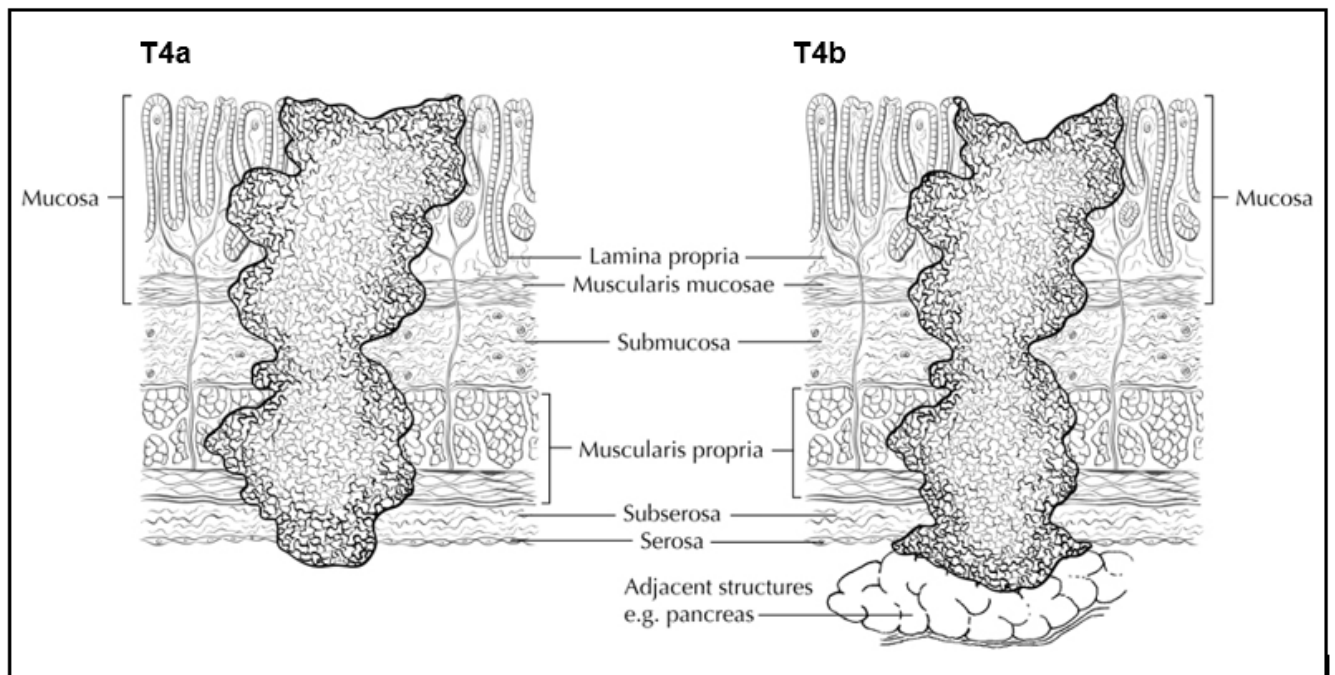


Figure 5. T4a tumor penetrates the serosa (visceral peritoneum) without invasion of adjacent structures, whereas T4b tumor invades adjacent structures, such as the pancreas (shown). Used with permission of the American Joint Committee on Cancer (AJCC), Chicago, IL. The original source for this material is the *AJCC Cancer Staging Atlas* (2006) edited by Greene et al² and published by Springer Science and Business Media, LLC, www.springerlink.com.

N Category Considerations

A designation of N0 should be used if all examined lymph nodes are negative, regardless of the total number removed and examined.¹ Lymph nodes containing isolated tumor cells, defined as single tumor cells or small clusters of cells not more than 0.2 mm in diameter, are classified as pN0. However, in treated gastric cancers, positive lymph nodes are defined as having at least one focus of residual tumor cells in the lymph nodes regardless of size.

Metastatic tumor deposits in the subserosal fat adjacent to a gastric carcinoma, without evidence of residual lymph node tissue, are considered regional lymph node metastases for purposes of gastric cancer staging.¹ Tumor deposits are defined as discrete tumor nodules within the lymph drainage area of the primary carcinoma without identifiable lymph node tissue or identifiable vascular or neural structure. Shape, contour, and size of the deposit are not considered in these designations. Nodules implanted on the peritoneal surface are considered distant metastases (M1).

References

1. Amin MB, Edge SB, Greene FL, et al, eds. *AJCC Cancer Staging Manual*. 8th ed. New York, NY: Springer; 2017.
2. Greene FL, Compton, CC, Fritz AG, et al, eds. *AJCC Cancer Staging Atlas*. New York: Springer; 2006.

K. Additional Findings

One of the most important risk factors for development of gastric carcinoma is long-standing infection with *Helicobacter pylori*, which leads to chronic gastritis and mucosal atrophy with intestinal metaplasia; autoimmune atrophic chronic gastritis, also a chronic inflammatory condition, is also associated with increased risk.¹ Occasionally, gastric carcinoma arises in a preexisting gastric polyp, most commonly large hyperplastic polyps in the setting of atrophic gastritis. Previous gastric surgery, such as Bilroth I or Bilroth II procedures for both benign and malignant indications, predisposes to the development of carcinoma in the remnant stomach; such tumors typically arise approximately 25 years after surgery for benign diseases.²

References

1. Kelley JR, Duggan JM. Gastric cancer epidemiology and risk factors. *J Clin Epidemiol*. 2003;56(1):1-9.
2. An JY, Choi MG, Noh JH, Sohn TS, Kim S. The outcome of patients with remnant primary gastric cancer compared with those having upper one-third gastric cancer. *Am J Surg*. 2007;194(2):143-147.